



PATIENT

Hedwig Gravette

SPECIES

Feline

BREED

DSH

SEX

Male Neutered

AGE

4.13.05

WEIGHT

8.25lbs

INTERPRETED BY

Maggie Machen Lamy,
DVM, DACVIM
(Cardiology)

HOSPITAL NAME

Banfil Towson

REFERRING VET

Dr. Culbertson

INVOICE

25375

DATE

7/18/22

PRESENTING CLINICAL SIGNS

History: Presented for dental. ProBNP snap was abnormal, and labs showed anemia.
 -Pertinent abnormal PE/Chem/CBC/UA Results: HCT 30, abnormal snap ProBNP.
 -Current medications: Gabapentin 0.3mL 50mg/mL PRN for arthritis, 1.25mg, Felimazole BID
 -Sedation used: Patient had 300mg of Gabapentin.
 -Pertinent previous ultrasound results: No previous.
 -STAT: Not requested
 -Imaging performed by: Andi Parkinson, BS, RDMS.

ECHOCARDIOGRAM FINDINGS

2D, m-mode, color flow and doppler imaging is available. The left ventricular wall is largely normal in dimension with regions of irregularity. The basilar septum measures increased. There is a diffusely hyperechoic endocardium consistent with fibrosis. The endocardium also appears mildly remodeled. The papillary muscles appear mildly remodeled. The left atrium is normal in size. Blood flow through the LVOT appears normal with no evidence of obstruction. The right atrium is normal in size. The right ventricle appears normal. The tricuspid valve appears normal in structure and mobility. No tricuspid regurgitation. The mitral valve is normal in structure and mobility with no mitral regurgitation. Blood flow through the RVOT is normal. No aortic insufficiency. No evidence of cardiac tumors or metastatic lesions on this scan.

CARDIAC CHART

| FELINE CARDIAC PARAMETERS | BODY WEIGHT (kg) | HR (BPM) | IVSd (cm) (Moise, Pipers) | LVIDd (cm) (Moise, Pipers) | LWVd (cm) (Moise, Pipers) | FS (%) | EF (%) |
|---------------------------|------------------|---------------------------------|--|----------------------------|---------------------------|----------------|-------------|
| NORMAL PARAMETER | ----- | 150-240 | 3.5-0.55 | <2 (mean 1.5) | 3.5-0.55 | 35-67 | 80-100 |
| PATIENT | 3.7 | 1.7 | 0.45 | 1.9 | 0.49 | 42 | 80 |
| FELINE CARDIAC PARAMETERS | LA/AO (Boon) | LA/AO HEART BASE (Swe) (Abbott) | LA 2D short axis Base view (cm) (Abbott) | | LVOT VEL (m/s) | RVOT VEL (m/s) | E max (m/s) |
| NORMAL | <1.5 | <1.3 | <1.2 | | <1.6 | <1.3 | <0.9 |
| PATIENT | NM | 1.3 | 1.3 | | 0.9 | 0.8 | NM |

Adapted from June Boon, Veterinary Echocardiography, 1998
 Abbott J & MacLean H JVIM 2006;20: 111-119, Moise et al. Am J Vet Res 47:1476, 1986. Pipers et al. Am J Vet Res 40:882, 1979.

INTERPRETATION OF THE FINDINGS & FURTHER RECOMMENDATIONS

The only abnormality appreciated is a focal septal bulge with significant LV remodeling and fibrosis. These findings may be indicative of early hypertrophic pathology or may simply represent a normal variant. Regardless, the left atrial dimension is normal, and there is minimal risk for complication at this time. No additional issues are identified.

Given these findings, no medications are indicated at this time.

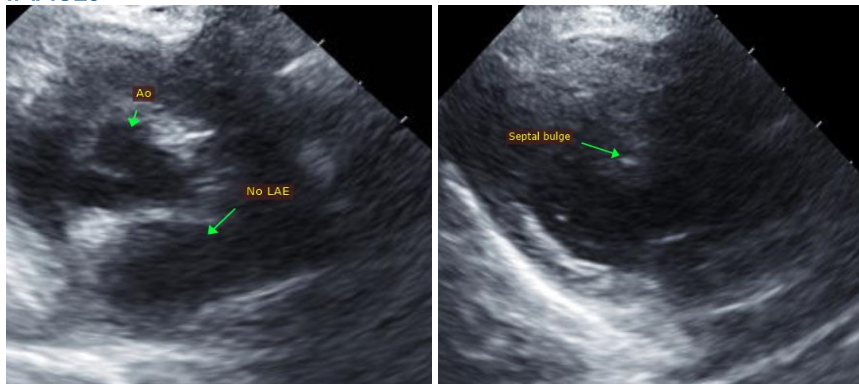
These findings may or may not explain BNP elevation pending follow up evaluation. Consider alternative contributing causes in this patient, such as kidney disease or hypertension.

If needed, the risk for general anesthesia is low, however heart rate stimulating drugs such as atropine, glycopyrrolate or ketamine should be avoided unless medically necessary. Even without significant pathology, with this degree of remodeling and diastolic stiffening there is a mildly elevated risk for fluid overload in this patient. Judicious IV fluid use is recommended. Additionally, a screening blood pressure is recommended in any older cat prior to general anesthesia.

Risk for complication with steroid use typically follows LA dilation, which in this case is low. That being said, any cat can experience unexpected signs of intolerance and monitoring of RR/RE is advised particularly in the initiation phase.

Recommend recheck echocardiogram in 1 year to screen for any progressive issues.

IMAGES



The information and recommendations provided are based on the images presented by the referring veterinarian. No evaluation can be communicated regarding pathology that was not visible in the image/video clips provided.

Thank you for this referral. This report was generated using transcription software, and minor dictation errors may be present. If the clinical or image interpretation does not parallel your findings or if I can be of any further assistance, please contact me.

Maggie Machen Lamy, DVM
Diplomate of the American College of Veterinary Internal Medicine (Cardiology)
info@sonopath.com